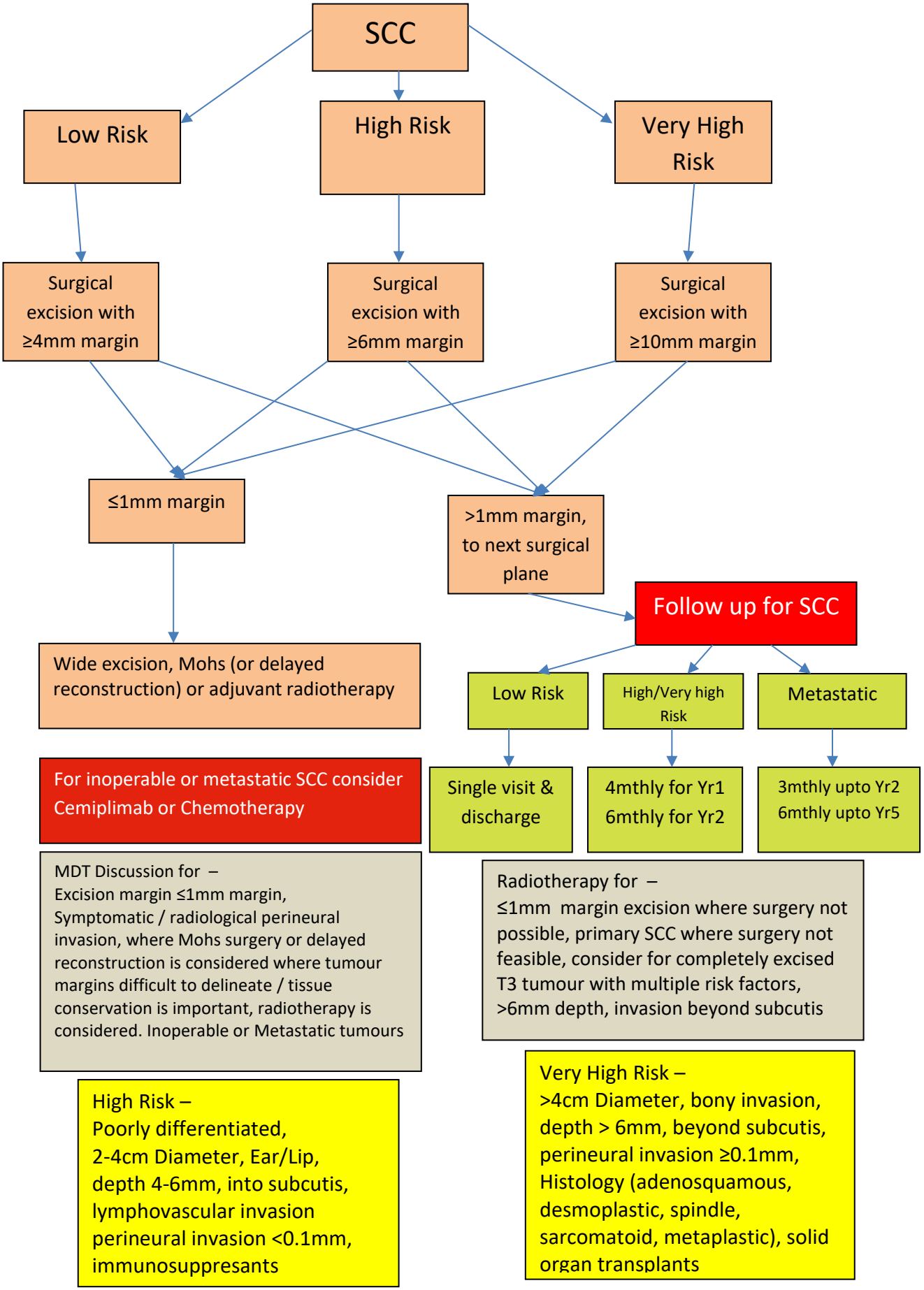
SCC
Low Risk
High Risk
Very High Risk
Surgical excision with ≥4mm margin
Surgical excision with ≥6mm margin
Surgical excision with ≥10mm margin
≤1mm margin
>1mm margin, to next surgical plane
Follow up for SCC
Wide excision, Mohs (or delayed reconstruction) or adjuvant radiotherapy
Low Risk
High/Very high Risk
Metastatic
For inoperable or metastatic SCC consider Cemiplimab or Chemotherapy
Single visit & discharge
4mthly for Yr1
6mthly for Yr2
3mthly upto Yr2
6mthly upto Yr5
MDT Discussion for –
Excision margin ≤1mm margin, Symptomatic / radiological perineural invasion, where Mohs surgery or delayed reconstruction is considered where tumour margins difficult to delineate / tissue conservation is important, radiotherapy is considered. Inoperable or Metastatic tumours
Radiotherapy for –
≤1mm margin excision where surgery not possible, primary SCC where surgery not feasible, consider for completely excised T3 tumour with multiple risk factors, >6mm depth, invasion beyond subcutis
High Risk –
Poorly differentiated, 2-4cm Diameter, Ear/Lip, depth 4-6mm, into subcutis, lymphovascular invasion perineural invasion <0.1mm, immunosuppresants
Very High Risk –
>4cm Diameter, bony invasion, depth > 6mm, beyond subcutis, perineural invasion ≥0.1mm, Histology (adenosquamous, desmoplastic, spindle, sarcomatoid, metaplastic), solid organ transplants